

A Phantom Study of Crosstalk Artefact Reduction using Interleaved Method in MR Lumbar

Wingghayarie Patra Gandhi^{1*}, Gatot Murti Wibowo², Nanang Sulaksono², Marichatul Jannah²

¹Dental and Oral Hospital of University Muhammadiyah Semarang, Radiological Department, 50273 Semarang City, Indonesia

²Poltekkes Kemenkes Semarang, Department of Radiodiagnostic and Radiotherapy Techniques, 50268 Semarang City, Indonesia

Abstract. Crosstalk artefacts appear as dark signal lines on MR images that occur due to imperfect multi-slice settings. There is still a good deal of emergence of crosstalk artefacts on T1 of SE and FSE sequence with interleaved slice acquisition methods. This study aims to determine the differences and the optimal value of reduction of crosstalk artefacts against changes in TR on T1 between SE and FSE sequences in interleaved slice acquisition methods. The experiment was carried out by scanning the water phantom with a variation of TR 500ms, 600ms, and 700ms in SE and FSE sequences. An assessment of the reduction of crosstalk artefacts was carried out using SNR values. There is a significant difference in the reduction of crosstalk artefacts between SE sequences and FSE on T1 (p -value = < 0.001). The reduction of crosstalk artefacts in SE sequences with TR values of 600ms and 700ms respectively, were 22.2% and 37.7%. Whereas the FSE sequences were 28.3% and 56%. Optimal crosstalk artefact reduction occurs in FSE sequences of T1 (56%). It is intended to use FSE sequences with TR 700ms on T1 if there are overlapping slices so that the crosstalk artefacts that occur will be reduced optimally.

1 Introduction

MRI is a diagnostic imaging modality that has a relatively safer advantage compared to the other examinations that use ionizing radiation. In addition, MRI can provide a good image quality to evaluate several diseases such as degenerative diseases, trauma, fractures, tumours and lesions in the bone, even malignancies in the spine [1–6]. One of the tests that can be done is a lumbar or lumbosacral spine MRI examination [7].

MRI examination of the lumbar spine has been the standard examination most often used to evaluate abnormalities in the lumbar spine with various indications and is the most sensitive examination to evaluate the presence of disc herniation [8], [9]. Disc herniation evaluation can be done in several areas in the axial plane such as the central canal, subarticular foramina, and extra foramina to evaluate the protrusion or extrusion of the disc

* Corresponding author: wingghayariepg@gmail.com

[10]. Under certain conditions, some of these areas may not be assessed properly due to an artefact [11].

Although some artefacts are relatively insignificant and easy to identify, artefacts that appear can interfere with anatomical imagery and pathological conditions or may cause inaccuracies in making a diagnosis [11], [12]. Artefacts that often occur in MRI examination of the lumbar spine are artefacts that arise due to the movement, Gibb's, metal and crosstalk (superposition slices) [13]. However, crosstalk artefacts are artefacts that most often appear on MRI examination of the lumbar spine [14].

Crosstalk artefacts occur due to imperfect multi-slice settings, so there are areas that are accidentally excited. If a proton is excited in a relatively short time compared to the relaxation time of T1, then superposition slices can experience the release of magnetization and signal loss. [15]. Crosstalk artefacts appear as signal lines with dark images on MR images that often resemble the shape of saturation bands. Parts of the image that experience crosstalk artefacts will look darker or hypo-intent because crosstalk artefacts can cause a decrease in SNR (Signal to Noise Ratio) [16].

There are recommendations to reduce crosstalk artefacts by using a slice gap of at least 30% or using interleaved slice acquisition techniques [16]. Meanwhile, previous studies have produced contradictory conclusions about the statement.

Previous research was carried out by scanning the phantom water with variations in TR values (500 ms, 600 ms and 700 ms) on the reduction of crosstalk artefacts between sequential and interleaved slice acquisition techniques in the SE (Spin Echo) sequence. The research concluded that the reduction of the largest crosstalk artefacts was produced by the acquisition technique of sequential slices, followed by an increase in TR values, this became irrelevant to the facts in the field [17].

Based on the unstructured observations that the authors have done, the most widely used slice acquisition technique is the interleaved slice acquisition technique. However, there are still many crosstalk artefacts appearing on MRI examination of the lumbar spine in both SE and FSE sequences with T1 weighted images especially on axial slices. Based on this, the authors tested the comparison of the reduction of crosstalk artefacts on the T1 weighted images of the SE and FSE sequences for variations in the increase in TR values in the interleaved slice acquisition technique.

2 Method

This type of research is a quantitative research experiment with a quasi-approach. The research has been carried out on water phantom objects with a volume size of 2000 ml, placed on the head coil in longitudinal position and scanned with 1.5 MRI Tesla modality. Variations apply to the TR value parameters that are equal to 500 ms, 600 ms, and 700 ms Each variation is carried out in SE and FSE sequences by controlling other parameters besides TR value parameters by the interleaved slice acquisition method.

Axial wedge scans are performed with a total of 10 slices divided into 2 groups of slices that form an angle of 45°. Groups of slices A and B each have 5 slices, the position of slice group A forms an angle of 0° to B1, while groups of slices B form an angle of 45° to B1. The intersection between groups of slices is arranged in the middle of the water phantom object. Here is Figure 1 which is the arrangement of axial slices in sagittal slices:



Fig. 1. Arrangement of axial slices in sagittal slices.

The scan was performed to obtain axial slices of the T1 weighted SE and FSE sequences with the provisions of the parameters in Table 1 as follows:

Table 1. Description of the research sample.

Parameters	T1					
	SE			FSE		
Time Repetition (ms)	500	600	700	500	600	700
Time Echo	24 ms			24 ms		
FA	90°			170°		
SG	0%			0%		
FOV	24 cm			24 cm		
Matriks	256			256		
Slice Thickness	4 mm			4 mm		
Bandwidth	150 Hz			150 Hz		
NEX	2			2		
ETL	-			3		

Data processing is done by calculating the SNR value of each slice obtained using the help of the ImageJ application with the ROI (Region of Interest) Manager tool. SNR measurements carried out in the area of crosstalk artefacts three times and calculate the average value on each slice obtained.

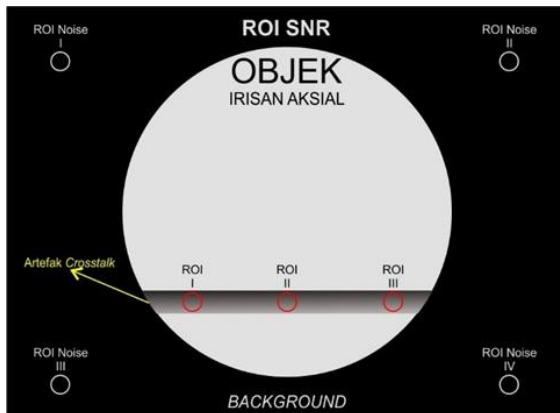


Fig. 2. SNR measurement location with ROI.

The analysis is carried out in several stages to test the hypotheses that have been formulated. After all, data have been completely collected, the analysis will be carried out using the Statistical Product and Service Solutions (SPSS) version 25.0 with a confidence level of 95% ($p\text{-value} = 0.05$).

The evaluation of the crosstalk artefact reduction is done using an assessment with the SNR value. In-depth analysis of the author is required regarding the determination of the reduction of crosstalk artefacts based on the theory as follows [18]:

$$\begin{aligned} \text{SNR} \downarrow &= \text{Crosstalk} \\ \text{Artefact} \uparrow \text{SNR} \uparrow &= \\ \text{Crosstalk Artefact} \downarrow & \end{aligned}$$

The SNR value of TR 500 ms is used as a benchmark to determine the reduction of crosstalk artefacts. Hypothesis testing is done with positive data from the results of the reduction of the SNR value of TR 700 ms with 500 ms, 600 ms with 500 ms.

3 Results and Discussions

This research was conducted during May-June 2019 on the object of water phantom research at Radiology Installation Telogorejo Hospital Semarang.

The research has been carried out on water phantom objects with a volume size of 2000 ml, placed on the head coil in longitudinal position and scanned with 1.5 MRI Tesla modality. Each scan performed, obtained as many as 10 slices of images in each of the 3 TR variations applied. So that the total number of images obtained is 30 slices (10×3). The following is a picture of the results of a phantom water scan in T1 weighted images SE (Fig. 3) and FSE (Fig. 4):




Fig. 3. T1 SE weighted images with TR (A) 500 ms, (B) 600 ms, and (C) 700 ms on I (1 - 5 ; 0 ° from B1) and II (6 - 10 ; 45 ° from B1).




Fig. 4. T1 FSE weighted images with TR (A) 500 ms, (B) 600 ms, and (C) 700 ms on I (1 - 5 ; 0 ° from B1) and II (6 - 10 ; 45 ° from B1).

The resulting axial wedge images are then measured and calculated to find the SNR value. To facilitate measurement and calculation, ROI is carried out with the help of the ImageJ application with the ROI Manager tool and Specific ROI with a diameter of 5 mm.

The data used for testing the hypothesis is only the data from the calculation of the crosstalk artefact reduction that occurs from the SNR value. The following is Table 2 data used in testing:

Table 2. SNR value of the calculation result of crosstalk artefact reduction.

SNR T1				
Slices	TR 700 ms – 500 ms		TR 600 ms – 500 ms	
	SE	FSE	SE	FSE
1	63.99	102.93	28.85	54.57
2	37.89	82.48	75.27	19.73
3	69.73	109.33	36.29	48.11
4	53.95	271.57	20.28	83.05
5	54.97	215.74	26.10	97.21
6	47.98	118.17	26.88	49.64
7	39.84	71.60	33.23	54.02
8	69.94	169.28	9.49	134.12
9	96.49	165.74	61.35	138.40
10	66.58	189.34	-4.72*	34.01*
* Data that is not used				

3.1 Reduction of Crosstalk Artefacts on Changes in Time Repetition in T1 Weighted Image between Spin Echo Sequence and Fast Spin Echo in Interleaved Sliced Acquisition Technique.

This test is carried out with the aim to determine the difference in crosstalk artefact reduction in TR changes in the T1 weighted image between the SE and FSE sequences in the acquisition technique of interleaved slices. Conclusions drawn on the T1 weighted image are based on the results of the paired T-test because the data used meets the assumptions of normal data. The following are Table 3 paired T-test different test results:

Table 3. Paired T-test different test results.

SNR T1 Value	Mean	Sig. (2-tailed)
SE – FSE	-66.10158	.000

The test results obtained a significance value <0.001 (<0.05). From the test results it can be stated that there is a difference in the reduction of crosstalk artefacts to changes in TR in the T1 weighted image between SE and FSE sequences in the interleaved slice acquisition technique.

Based on the results of hypothesis testing, the reduction of crosstalk artefacts is significantly different between SE sequences and FSE. The difference in the reduction of crosstalk artefacts between SE and FSE sequences is evidenced from the significance value of the results of the paired T-test difference test <0.05 . The significance value of the difference in the crosstalk artefact reduction between SE and FSE sequences on T1 weighted image is <0.001 . The results of the test concluded that there was a difference in the reduction of crosstalk artefacts on TR changes in the T1 weighted image between SE sequences and FSE in the interleaved slice acquisition technique.

Differences in the reduction of crosstalk artefacts that occur between SE and FSE sequences are analysed due to differences in factors that affect the SNR value. In the FSE sequence, each echo experiences a different amount of intrinsic T2 decay, which results in differences in image contrast when compared with SE from similar TR and TE [12]. So the SNR value generated by the FSE sequence will be different from the SE sequence. This is supported by the results of previous studies which stated that there is an influence of the ETL value used on the SNR value generated [19].

3.2 Reduction of Optimal Crosstalk Artefacts Resulting from Changes in Time Repetition in the T1 Weighted Image between the Spin Echo Sequence and the Fast Spin Echo in the Interleaved Slice Acquisition Technique.

This analysis was carried out with the aim of finding out the reduction of optimal crosstalk artefacts produced against TR changes in the T1 weighted image between SE and FSE sequences in the interleaved slice acquisition technique. Analysis on T1 image weighted is done by looking at the paired sample statistics table (Paired Samples Statistics) from the results of the paired T-test different tests. Here are Table 5 test results of paired sample statistics:

Table 4. Paired samples test results statistics.

SNR T1 Value	Mean
SE	48.3737
FSE	114.4753

In the test results obtained by the highest mean value is owned by the SNR value of T1 weighted image in the FSE sequence that is equal to 114.4753. To find out the optimal TR value on the T1 weighted image SE and FSE sequences in reducing the crosstalk artefact, it can be done by looking at Fig 5 chart of the value of the crosstalk artefact reduction to the change in TR value on the T1 weighted image sequences SE and FSE sequences as follows:

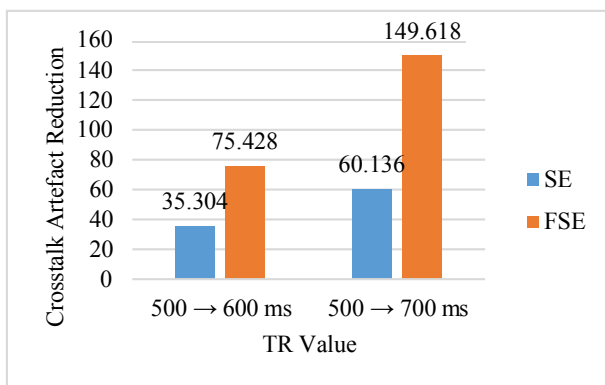


Fig. 5. Chart of reduction value of crosstalk artefact towards changes in TR value of SE and FSE sequences.

In Figure 5 it can be seen that the highest reduction of crosstalk artefacts is at TR 700 ms, both in SE and FSE sequences. Following is Table 5 reductions of crosstalk artefacts to changes in TR values in the T1 weighted image of SE and FSE sequences:

Table 5. Reduction of crosstalk artefacts to changes in TR values in the T1 weighted image sequences SE and FSE.

Mean Value of SNR TR 500 ms		Reduction (SNR)		Reduction (%)	
SE	FSE	SE	FSE	SE	FSE
159.338	266.8110				
TR					
(600 ms – 500 ms)		35.304	75.428	22.2	28.3
(700 ms – 500 ms)		60.136	149.618	37.7	56

Table 5 shows that increasing the TR 500 ms to 600 ms resulted in a 22.2% reduction in crosstalk artefacts in the SE sequence and 28.3% in the FSE sequence. While an increase in TR 500 ms to 700 ms results in a 37.7% reduction in crosstalk artefacts in the SE sequence and 56% in the FSE sequence. The highest reduction in crosstalk artefacts was 37.7% in SE sequences and 56% in FSE sequences.

Crosstalk artefacts appear as signal lines with dark images on MR images that often resemble the shape of saturation bands. Parts of the image that experience crosstalk artefacts will look darker or hypo-intent because crosstalk artefacts can cause a decrease in SNR [16]. If there is an increase in SNR, then the dark level in the part of the image that has a crosstalk artefact will decrease so that the crosstalk artefact will decrease.

The results of the analysis of optimal crosstalk artefact reduction on TR changes in the T1 weighted image between the SE and FSE sequences obtained the highest mean value in the FSE sequence that is equal to 114.4753. This means that the optimal reduction of crosstalk artefacts occurs in the FSE sequence of T1 weighted images. The mean value is directly proportional to the magnitude of the reduction in the crosstalk artefact that occurs, the greater the mean value, the reduction in the crosstalk artefact that occurs is also greater. The test results can also be proven by the percentage value of the crosstalk artefact reduction that occurs between the SE and FSE sequences on T1 weighted image. In SE sequences, crosstalk reduction only occurred in 37.7%, whereas in FSE sequences, it was greater at 56%. The highest percentage reduction in crosstalk artefacts occurred at TR 700 ms, both SE and FSE sequences.

The increase in the value of the SNR that occurred to increase the value of TR is supported by the results of previous studies which stated that the value of the SNR has increased exponentially in the TR value between 100 ms to 700 ms [20]. As for the results of other studies that support the results of this study are the results of previous studies which stated that the reduction of the largest crosstalk artefacts was produced by the acquisition technique of sequential slices followed by an increase in TR values [17].

Aside from the superior aspect of reducing crosstalk artefacts, the FSE sequence is also superior to the scan time aspect. At the time of data collection, the average scan time of the FSE sequence is shorter than that of the SE sequence. This adds to the superior quality of the image owned by the FSE sequence, because the scan time is also one aspect that affects the quality of the MR image [18]. If the scan time is longer it will increase the likelihood of other artefacts appearing such as ghosting and blurring artefacts due to the movement of the object being examined [15].

The author suggests using FSE sequences with TR 700 ms in T1 weighted images if there are overlapping slices or superposition so that the crosstalk artefacts that occur will be optimally reduced. Further research needs to be done to determine the results of application in the field with patients as research subjects and a qualitative assessment by a radiology doctor on the quality of image information and link it with the scan time aspects required.

4 Conclusion

There is a significant difference in the reduction of crosstalk artefacts between SE and FSE sequences of T1 weighted images. Reduction of optimal crosstalk artefacts occurred in FSE sequences which occurred by 56% in T1 weighted images with TR 700 ms.

References

1. S. Buhmann (Kirchhoff), C. Becker, H. R. Duerr, M. Reiser, and A. Baur-Melnyk, Detection of osseous metastases of the spine: Comparison of high resolution multi-detector-CT with MRI, *Eur. J. Radiol.*, **69**, 567–573 (2009).
2. V. Hartwig, G. Giovannetti, N. Vanello, M. Lombardi, L. Landini, and S. Simi, Biological effects and safety in magnetic resonance imaging: a review., *Int. J. Environ. Res. Public Health*, **6**, 1778–98 (2009).
3. A. K. Ganiyusufoglu, L. Onat, O. Karatoprak, M. Enercan, and A. Hamzaoglu, Diagnostic accuracy of magnetic resonance imaging versus computed tomography in stress fractures of the lumbar spine, *Clin. Radiol.*, **65**, 902–907 (2010).
4. M. Jacob, Pattern of spine degenerative disease among patients referred for lumbar magnetic resonance imaging at Muhimbili National Hospital, Dar es salaam, Tanzania March-September-2010., Accessed: Jan. 03, 2019. [Online] (2010).
5. M. Henry, R. I. Riesenburger, J. Kryzanski, A. Jea, and S. W. Hwang, A retrospective comparison of CT and MRI in detecting pediatric cervical spine injury, *Child's Nerv. Syst.*, **29**, 1333–1338 (2013).
6. M. B. Lange, M. L. Nielsen, J. D. Andersen, H. J. Lilholt, M. Vyberg, and L. J. Petersen, Diagnostic accuracy of imaging methods for the diagnosis of skeletal malignancies: A retrospective analysis against a pathology-proven reference, *Eur. J. Radiol.*, **85**, 61–67 (2016).
7. A. Rao, A. Mishra, Y. Pimpalwar, R. Sahdev, and N. Yadu, Incorporation of Whole Spine Screening in Magnetic Resonance Imaging Protocols for Low Back Pain: A Valuable Addition, *Asian Spine J.*, **11**, 700 (2017).
8. P. Suthar, R. Patel, C. Mehta, and N. Patel, MRI evaluation of lumbar disc degenerative disease., *J. Clin. Diagn. Res.*, **9**, TC04-9 (2015).
9. R. Ngnitewe Massa and F. B. Mesfin, *Herniation, Disc*. StatPearls Publishing (2018).
10. D. F. Fardon, A. L. Williams, E. J. Dohring, F. R. Murtagh, S. L. Gabriel Rothman, and G. K. Sze, Lumbar disc nomenclature: version 2.0: Recommendations of the combined task forces of the North American Spine Society, the American Society of Spine Radiology and the American Society of Neuroradiology., *Spine J.*, **14**, 2525–45 (2014).
11. J. Elliott, T. Flynn, A. Al-Najjar, J. Press, B. Nguyen, and J. T. Noteboom, The Pearls and Pitfalls of Magnetic Resonance Imaging for the Spine, *J. Orthop. Sport. Phys. Ther.*, **41**, 848–860 (2011).
12. J. T. Bushberg, J. A. Seibert, E. M. Leidholdt, and J. M. Boone, *The essential physics of medical imaging* (2012).
13. T. Budrys, V. Veikutis, S. Lukosevicius, R. Gleizniene, E. Monastyreckiene, and I. Kulakiene, Artifacts in magnetic resonance imaging: how it can really affect diagnostic image quality and confuse clinical diagnosis?, *J. Vibroengineering*, **20**, 1202–1213 (2018).
14. E. Lavdas *et al.*, Elimination of motion, pulsatile flow and cross-talk artifacts using blade sequences in lumbar spine MR imaging, *Magn. Reson. Imaging*, **31**, 882–890 (2013).
15. L. Saba, *Image principles, neck, and the brain* (2016).
16. C. Westbrook and J. (Writer on magnetic resonance imaging) Talbot, *MRI in practice* (2019).
17. S.-Y. Lee *et al.*, A study on a method to reduce the effect of the cross-talk artifact in a simultaneous, multiple-slice, plane, oblique MRI scan, *J. Korean Phys. Soc.*, **61**, 807–814 (2012).
18. C. Westbrook, *Handbook of MRI technique* (2014).

19. N. C. Prabawati, S. Masrochah, and S. Mulyati, Analisis TSE Factor Terhadap Signal to Noise Ratio dan Contrast to Noise Ratio pada Pembobotan T2 Turbo Spin Echo Potongan Axial MRI Brain, *J. Imejing Diagnostik*, **3**, 271 (2015).
20. A. Tanjung Aji Prastowo, W. Setiabudi, and dan Choirul Anam, Korelasi Nilai Time Repetition (TR) Dan Time Echo (TE) Terhadap Signal To Noise Ratio (SNR) Pada Citra MRI, *Bad. Pen. Jur. Fis. Uni. Dip. Berkala Fisika*, **16**, 103-110 (2013).